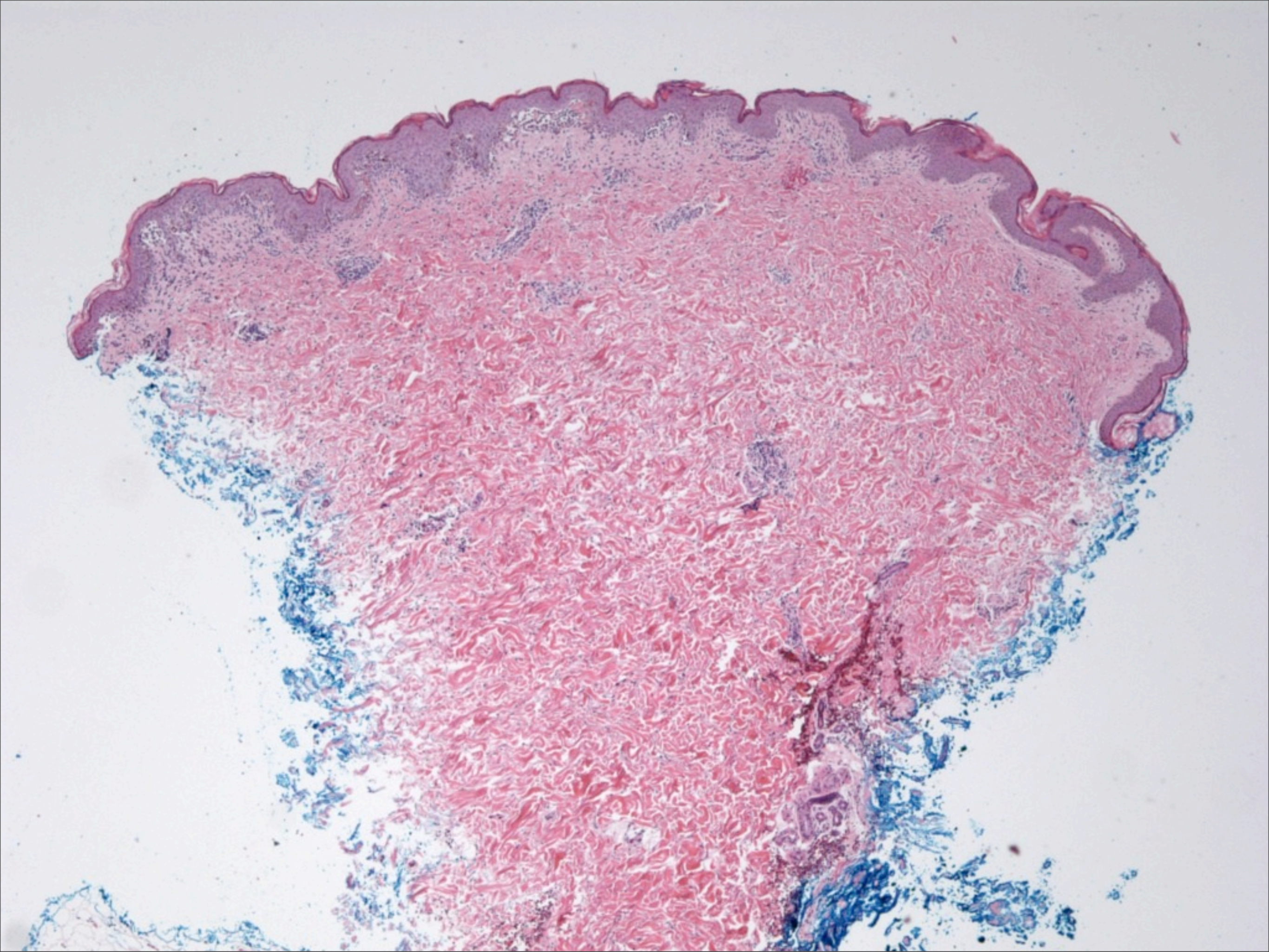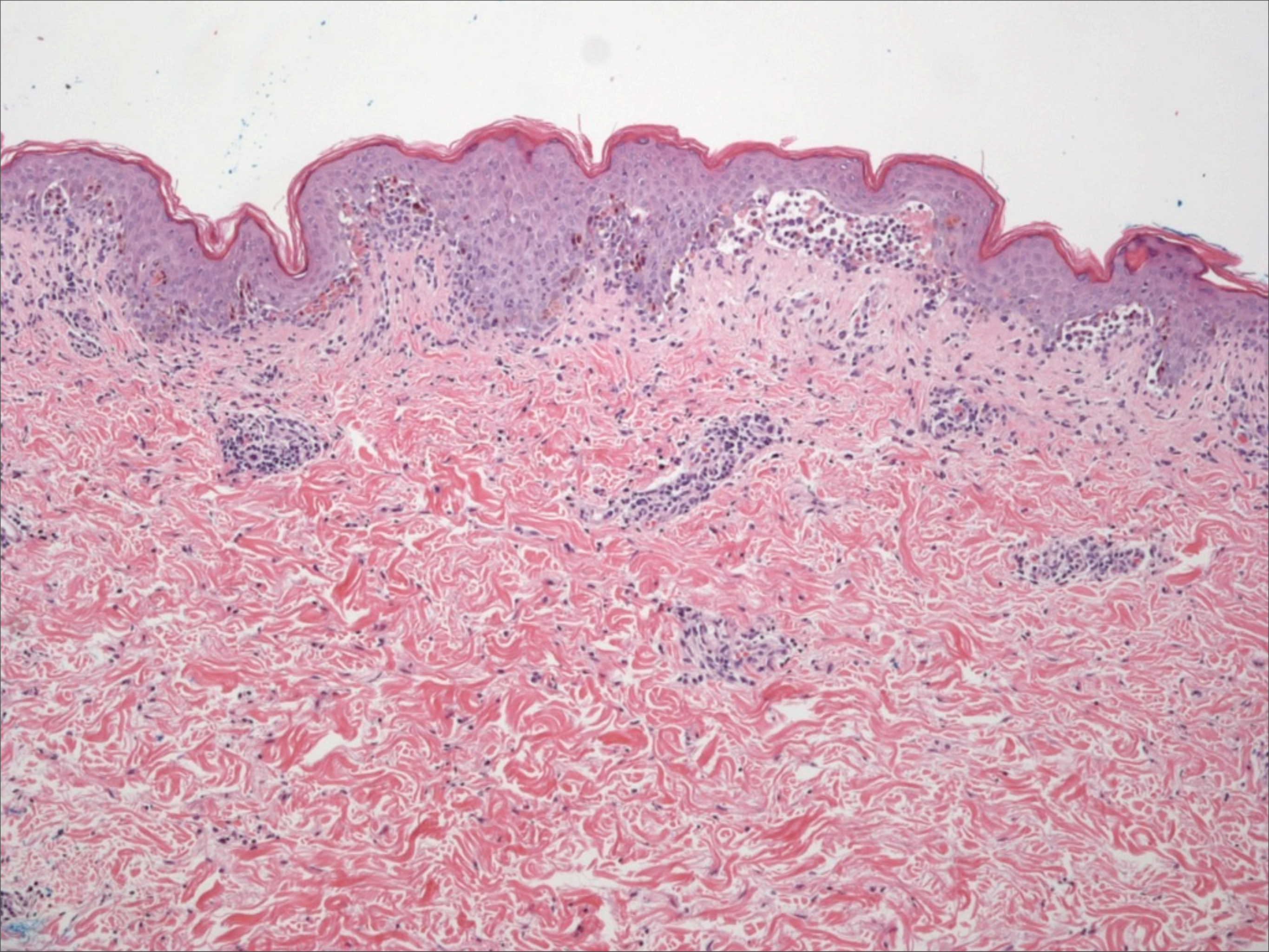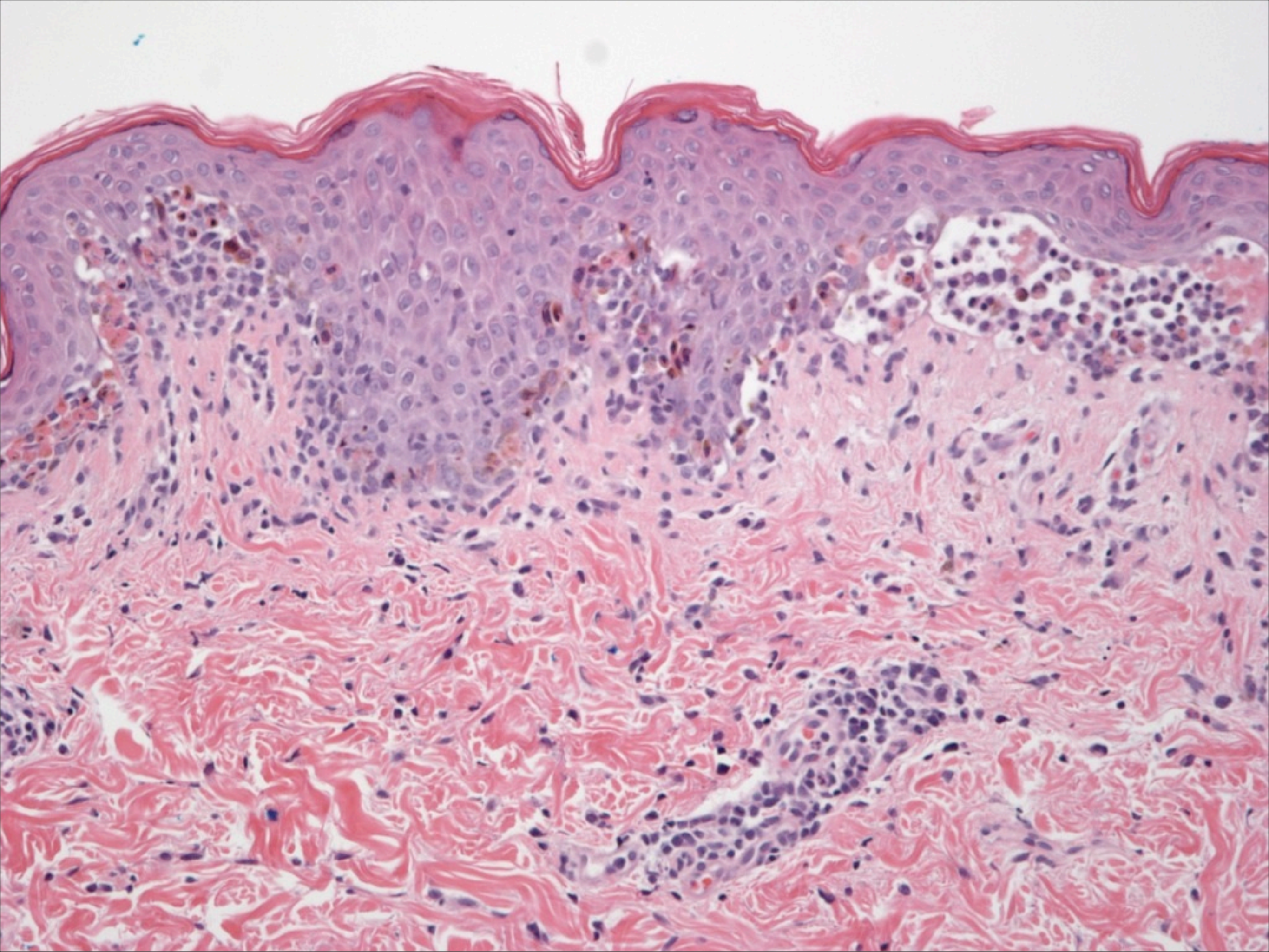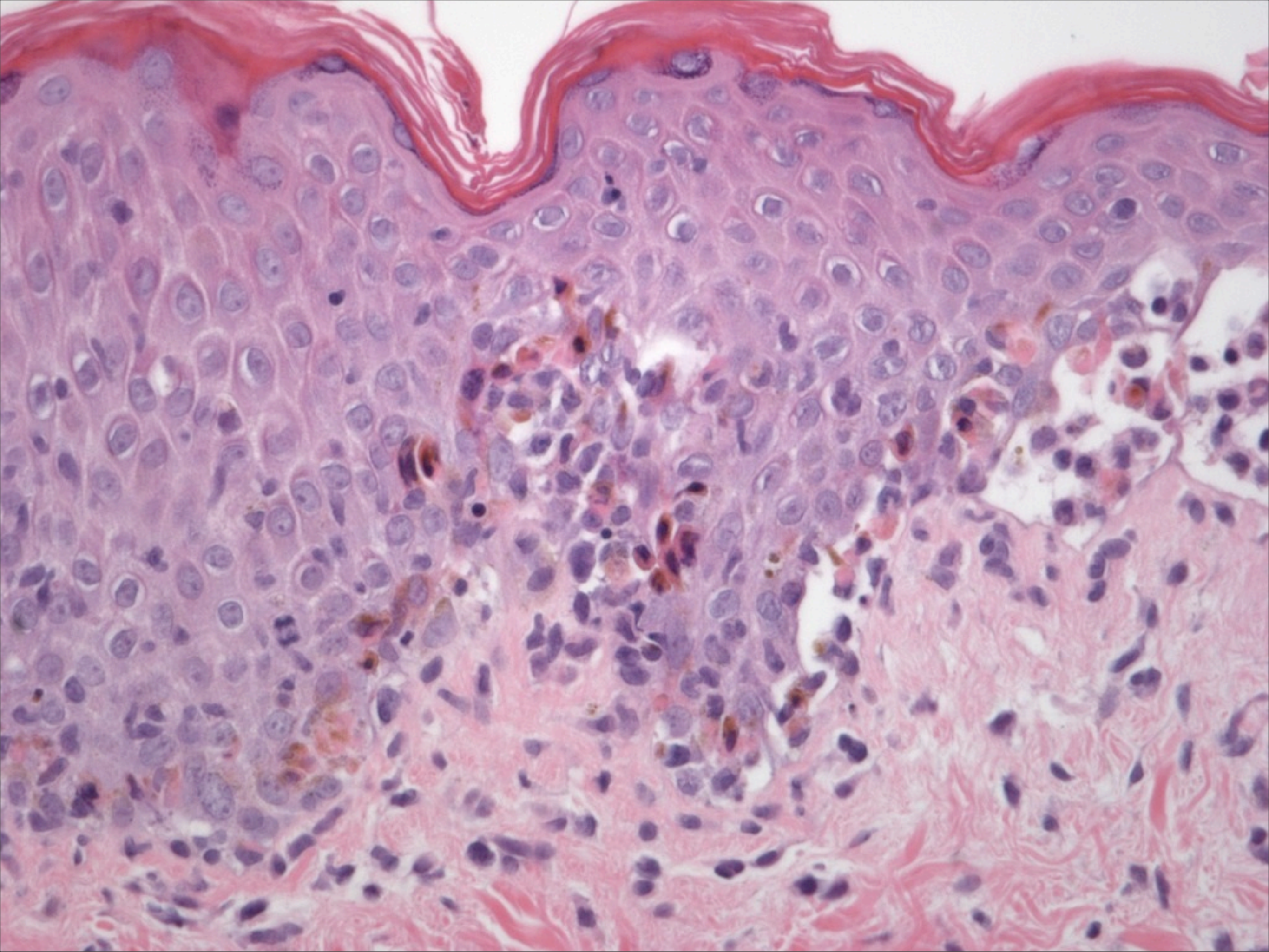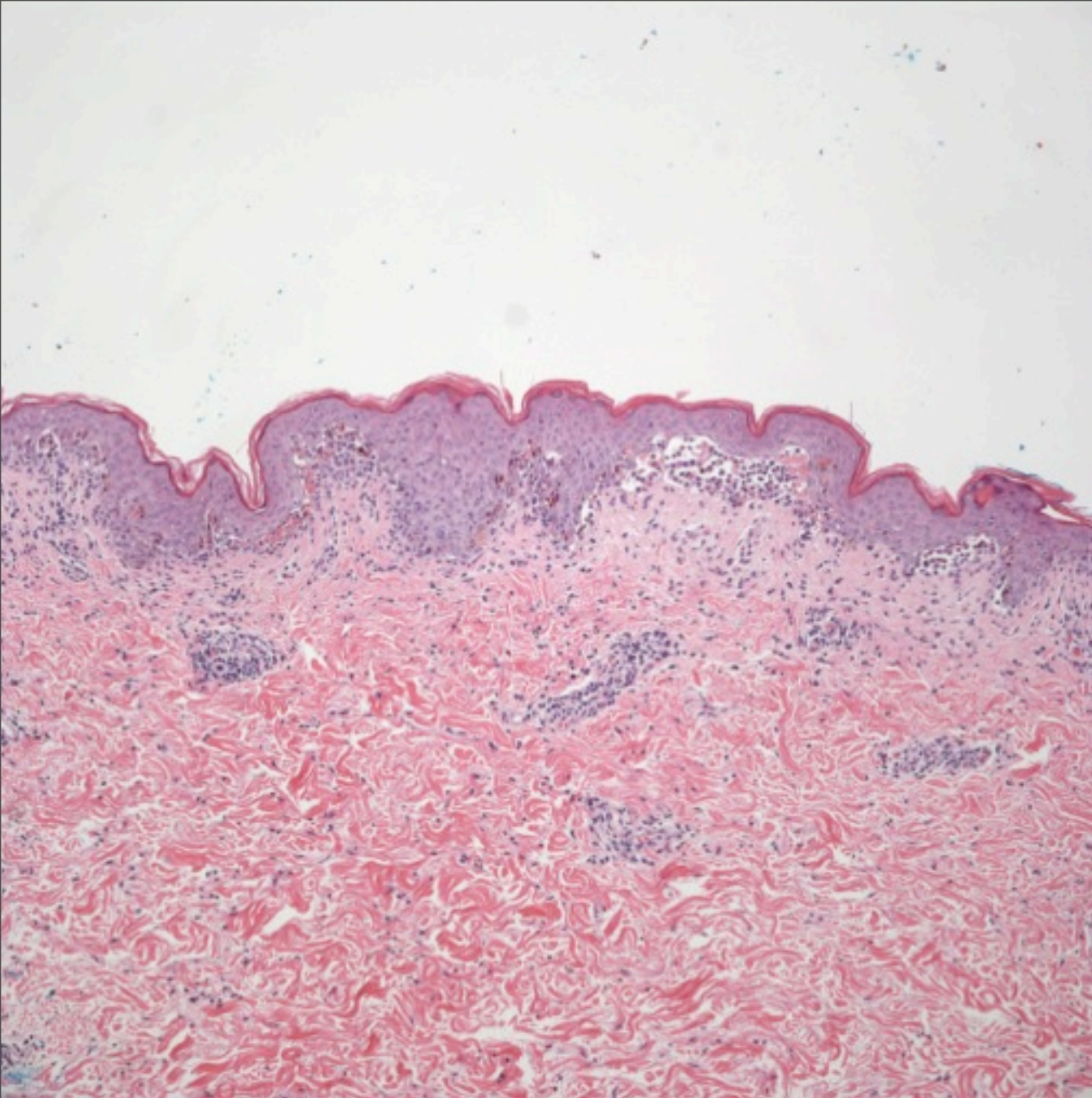


Erythema Multiforme



Acute Interface Dermatitis
with Lymphocytes

Variable eosinophils

Dyskeratotic keratinocytes

May show subepidermal vesicle/blister